

SURGERY OF CRANIOSYNOSTOSIS IN ZAGAZIG: POSTOPERATIVE OUTCOME

Moustafa M. El-Saadi M.D., Mohamed H. Abd-Elaal M.D., Alaa N. El-Sadek M.D. and Emad Salah Ibrahim M.Sc*

General Surgery Department, Faculty of Medicine, Zagazig University

ABSTRACT

Background and Objective: Craniosynostosis is defined as the premature closure of a cranial suture or sutures, leading to alterations in head shape. It is a common physical finding in children. Craniosynostosis occurs in approximately 1:2500 live births. The aim of the study was to evaluate the postoperative outcome of surgery of craniosynostosis in Zagazig University Hospitals. **Patients and Methods:** A total of 18 patients with craniosynostosis were treated surgically at the plastic Surgery Unit in Zagazig University Hospital. Standard fronto-orbital advancement and forehead reshaping was performed in all cases. The postoperative surgical outcome assessment was based on clinical examination, CT measurements (supra-orbital rim projection and frontal stenosis ratio) and Whitaker et al., 1987 classification. **Results:** The mean operative time was 253.9 minutes and the mean postoperative hospitalization time was 12.4 days. According to Whitaker et al., classification, most cases showed excellent results (56.3%). Surgical complications were observed in 8 patients (38.9 %): In 5 patients there were dural tear, one patient had haematoma at incision line, and one patient had subcutaneous infection, and one patient had CSF leakage. **Conclusion:** A multidisciplinary approach and appropriate training of the clinical surgical staff can minimize the risks and decrease the complications in the treatment of craniosynostosis, leading to a satisfactory outcome

Keywords: craniosynostosis, front-orbital advancement and postoperative outcome

INTRODUCTION

Craniosynostosis is the term referring to a set of characteristic skull deformities that occur as a result of premature fusion of various cranial vault sutures. This condition may be either syndromic or nonsyndromic. Syndromic forms are associated with a specific facial, trunkal, and extremity deformities, depending on the underlying genetic abnormalities. Non syndromic craniosynostosis is the most common form and usually affects single suture. Its occurrence result in specific craniofacial deformities, depending on the affected suture^[1].

This condition occurs in approximately 1 in 2500 live births. Sagittal suture synostosis is the most common form, occurring in 40 – 60 % of cases followed by unilateral and bilateral coronal synostosis which together account for 20 to 30 % of cases. Unilateral coronal synostosis is approximately twice as common as is the bilateral form. Metopic synostosis account for roughly 10 % of cases where true lambdoid suture synostosis does an extremely rare occurrence constitutes only 3% to 5% of case^[1].

Cranial reconstruction for patients presenting with craniosynostosis has become the standard of care. The goal of surgical correction for these patients is 2-fold: (1) to expand the intracranial volume, thereby allowing unimpeded cerebral growth; and (2) to improve the aesthetic appearance of the child^[1].

Defining the outcome of the various surgical approaches should be an essential part of the

treatment for synostosis, especially when correction of the deformity is a primary surgical indication^[1]. There are many objective ways of measuring the postoperative change that occur in the cranial bones following corrective surgery, including the cephalic index^[2] as well as photography^[5].

The supra-orbital rim projection was measured from the longitudinal orbital projection by making a line extending from the inferior orbital rim (mid point of the inferior orbital rim) tangent to the corneal surface upward then the shortest distance is measured between this line and the supra-orbital rim. The later distance determine the position of the supra-orbital rim (retruded or protruded). When the superior orbital rim lies anterior to this line, it is considered to be protruded (positive value). When the superior orbital rim lies posterior to this line, it is considered to be retruded (negative value) (fig. 1). Accurate correction when the superior orbital rim lies on this line (0 values)^[6].

The frontal stenosis ratio was defined as the ratio of the interparietal distance (IPD) to the intercoronal distance (ICD) according to the method introduced by Posnick et al. in 1994 and further modified by Bottero et al. Bottero et al have taken these readings one stage further and used the ratio of the interparietal to the intercoronal distance to assess the degree of frontal stenosis (fig.2). Shimoji subsequently determined the IPD/ICD to be 1.21 in normal children^[7].

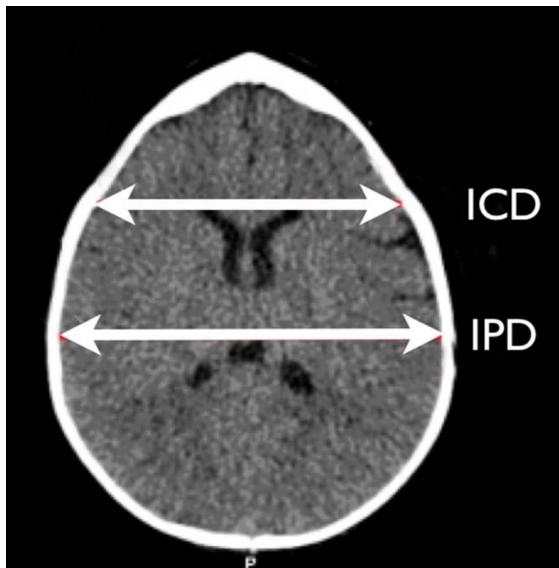


Fig. (1)

Figure 1: CT image (axial view) demonstrates the supra orbital rim recession measurement [6].

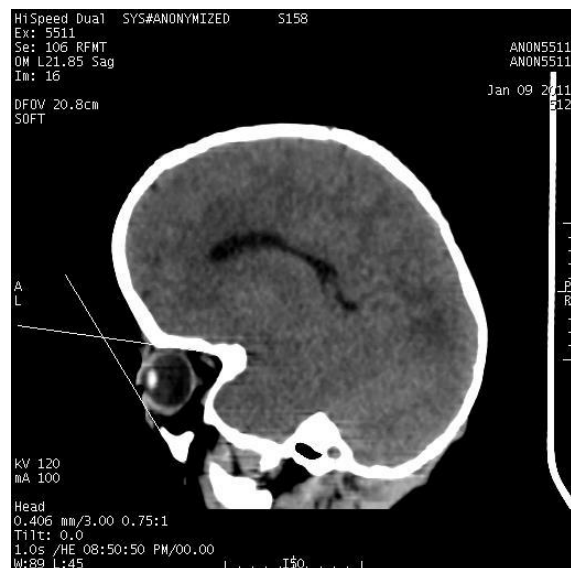


Fig. (2)

Figure 2: Evaluation of frontal stenosis degree on computed tomography. a, intercoronal distance. b, interparietal distance [7].

PATIENTS AND METHODS

All patients selected in this study were managed at Plastic and Reconstructive Unit in Zagazig University Hospitals. From August 2008 to August 2011, 18 patients with craniosynostosis were included in this study.

The inclusion criteria were: 1- Patients with any type of craniosynostosis. 2- Age of the patients at time of surgery was below 18 months. The exclusion criteria were: 1- Patients without Standard preoperative and 1- year postoperative CT scan available on optical discs. 2- Patients with increased intracranial tension

We categorized our patients into 3 groups according to the affected suture: Unilateral coronal synostosis included 7 patients, bilateral coronal synostosis included 7 patients (4 of them were Apert syndrome), and metopic synostosis included 4 patients.

Diagnosis was confirmed after a history taking, general examination, and radiography of the skull. All patients underwent computed tomographic scanning to exclude hydrocephalus and other cranial or cerebral abnormalities. Preoperative assessment was carried out immediately before surgery and included pediatric clinical evaluation, blood coagulation tests, hemogram, urea and electrolyte estimations, and blood cross-matching. All patients were photographed immediately preoperative; anterior posterior view, lateral view (right and left), and top view. These photographs were compared with 1- year postoperative photographs.

The outcome of the surgical treatment of our cases was evaluated by: (1) All patients were subjected to preoperative and 1- year postoperative head CT. The following measurements were evaluated: The supra-orbital rim projection (retrusion or protrusion) for unicoronal and bicoronal synostosis cases and the frontal stenosis for metopic synostosis cases, (2) The Whitaker et al., 1987 [8] classification and the definitions for each category according to the article of Whitaker et al as follow: **Category I** is defined as those patients in whom no refinements or surgical revision was advised or necessary per the patient or the surgeon. In **category II**, soft tissue or lesser bone contouring revisions were desired, regardless if performed or not. In **category III**, major alternative osteotomies or bone grafting procedures were needed or performed, yet these procedures were not as extensive as the original procedure. In **category IV**, a major craniofacial procedure was again or will be required, and the procedure will be either as great as or greater in magnitude than that of the original surgery, (3) Complications were defined as any event requiring prolonged hospitalization, readmission secondary to the surgical procedure, any reoperation relating to the original surgery, or any mortality.

OPERATIVE TECHNIQUE

Operations were carried out under general anaesthesia. Intravenous antibiotics in the form of third generation cephalosporin were administered at the time of induction of anaesthesia and

continued for 7 days postoperatively. Standard fronto-orbital advancement and forehead reshaping were performed for all cases with some minor variations according to each patient skull deformity. The children were operated in supine position with ante flexion of the head using a small pillow. After shaving and disinfection a solution of epinephrine (1: 200.000) was infiltrated prior to the incision.

The steps of surgery are illustrated in operative photos 1-6. A bicoronal incision was used and the anterior scalp flap was elevated epiperosteally up to a position 2 cm above the supra orbital margin, the temporalis muscle was dissected laterally in a subperiosteal plan. Bilateral circumferential subperiosteal orbital dissection with the release of the lateral canthi, but with preservation of integrity of the medial canthi and the nasolacrimal apparatus, the subperiosteal dissection continued laterally along lateral orbital rim till the fronto-zygomatic suture. The posterior scalp flap was dissected epiperosteal to a position between coronal and lambdoid sutures. Bifrontal osteotomy was performed including removal of the coronal suture which was synostosed in most cases, leaving one centimeter above the supraorbital bar.

Extensive dural undermining was done in anterior calvarial vault continuing to the lateral aspect of the cranial base then the frontal bone was removed as indicated. The most lateral aspect of the coronal suture was radically removed with rongeurs including a part of the greater and lesser wings of sphenoid bone. The frontal and temporal lobes of the brain were gently retracted to allow for safe upper orbital osteotomies through the skull base. Care was taken to remain anterior to olfactory bulbs. The supra orbital bar was isolated from the orbit by cutting pterion laterally, across the orbital roof, to nasion medially.

The supra orbital bar was realigned by thinning the bone on its posterior surface, especially near the superolateral orbital rim, to facilitate bending and reshaping according to the type of the deformity and the clinical type of craniosynostosis, our cases were mainly coronal(unilateral and bilateral) and metopic synostosis . The supra orbital bar was advanced and then fixed to the facial skeleton by absorbable polyglycolic acid sutures. Stabilization was achieved by titanium mini plates and screws to fix the supra orbital bar to each corresponding parietal bone.

The forehead craniotomy segment was modulated to create an appropriate anterior cranial vault volume and symmetric forehead shape. The modified frontal bone was fixed to supraorbital

bar and to each other with polyglycolic acid sutures. An osseous defect was left behind and above the fronto-orbital region, which re-ossified slowly. The temporal muscles were advanced anteriorly and fixed to the lateral orbital rim with polyglycolic acid sutures. The wound is closed in two layers over a drain. The miniplates and screws were removed one month postoperative through small incisions at the eye brow and above the ear.

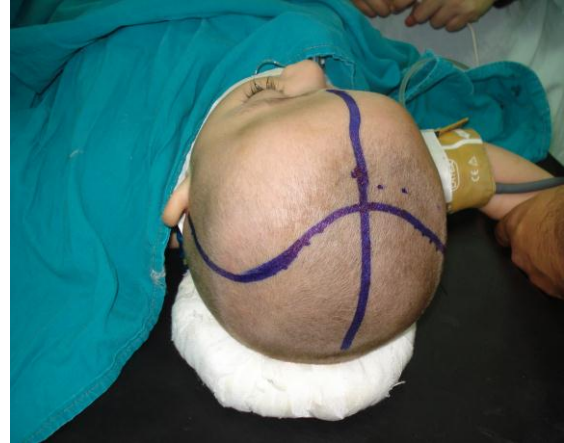

Photo 1: Marking of bicoronal incision.

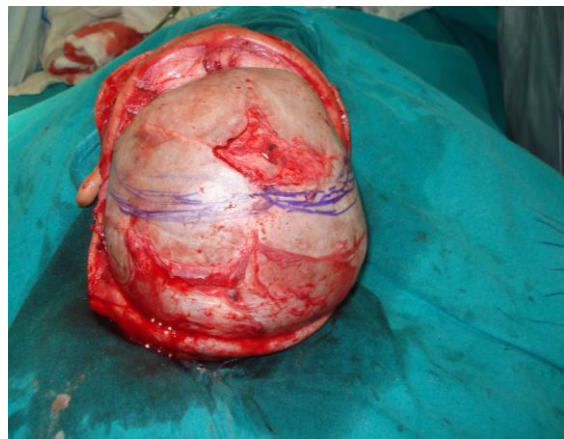

Photo 2: The frontal scalp elevation and both orbit subperiosteal dissection.

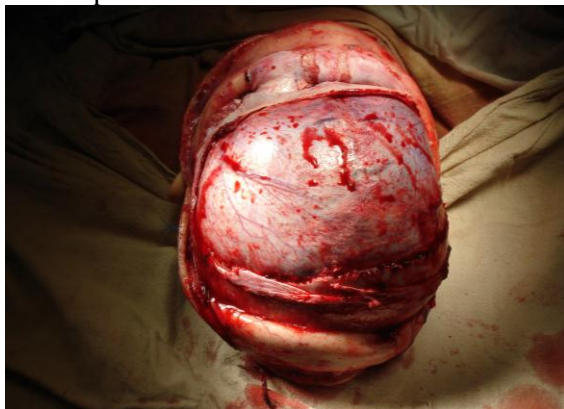

Photo 3: Dura covering the brain after removal of the frontal bone flap.

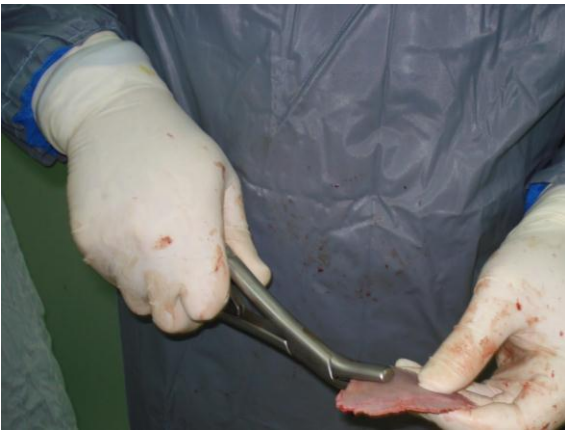

Photo 4: Reshaping and remodeling of the frontal bones.

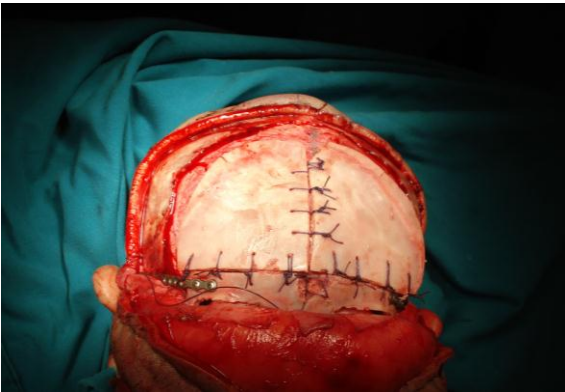


Photo 5: Anteroposterior view showing: 1- Fixation of supraorbital bar to parietal bone by miniplates and screw. 2- Fixation of the frontal bones to the supraorbital bar.

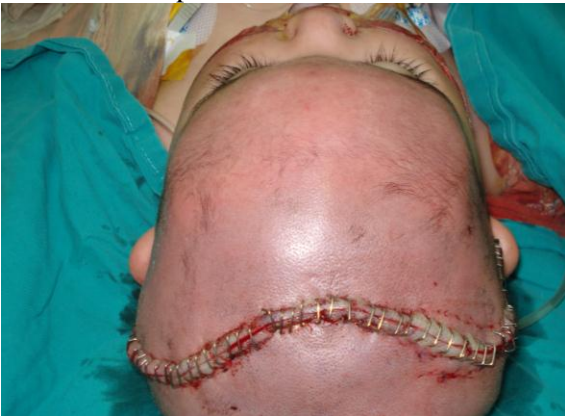

Photo 6: At the end of the procedure.

RESULTS

This study included 18 patients; 10(55.6%) males and 8 (44.4%) females. The average age at time of operation was (10.11) months (variation, 8 m to 14 m). The minimum weight found was 8 kg and the maximum was 11.5 kg (average, 9.47 kg).

The types of deformities found on the study were unilateral coronal synostosis [n = 7(38.9%)], bilateral coronal synostosis [n = 7 (38.9%)], and metopic synostosis [n = 4 (22.2%)]. In this study there were 4 (22.2%) syndromic patient, in the form of Apert syndrome.

The surgical technique used in this study was fronto orbital advancement and remodeling in all cases, the operative time ranged from 230 m to 330 m (mean operative time was 253.9 m) and the Postoperative hospitalization time ranged from 7 to 30 days, with a mean of 12.4 days.

The quantitative CT scan results

1- The supra orbital rim projection

In both bilateral and unilateral coronal synostosis there was significant difference between the mean preoperative and postoperative supra orbital rim projection (tables 1&2).

2- The frontal stenosis ratio:

In the metopic group, there was significant difference between the pre and postoperative frontal stenosis ratio (table 3).

Table (1): Difference in the Mean score (SD) of supra orbital rim projection (SOP) before and after operation within the bicoronal synostosis cases

| | Bicoronal group (6 patients) | | Paired t Test | P-value |
|--------------------------|---|-----------|--------------------------|----------------|
| | Mean | SD | | |
| Preoperative SOP | 9.71 | 1.11 | t = 17.4 | < 0.001 * |
| Postoperative SOP | 0.86 | 1.07 | | |

* There is a highly statistical significant improvement in the Mean score of SOP after operation of bicoronal synostosis cases.

Table (2): Difference in the mean score (SD) of supra orbital rim projection difference (SOPD) before and after operation within unicoronal synostosis cases

| | Unicoronal group (6 patients) | | Paired t test | P-value |
|---------------------------|--|-----------|--------------------------|----------------|
| | Mean | SD | | |
| Preoperative SOPD | 12.39 | 0.98 | t = 25.2 | < 0.001 * |
| Postoperative SOPD | 1.43 | 1.4 | | |

* There is a highly statistical significant improvement in the Mean scores of SOPD after operation of unicoronal synostosis cases.

Table (3): Difference in the mean scores (SD) of Frontal Stenosis (FS) before and after operation within metopic synostosis cases

| | Metopic group (4 patients) | | Paired t Test | P-value |
|-------------------------|---------------------------------------|-----------|--------------------------|----------------|
| | Mean | SD | | |
| Preoperative FS | 1.4 | 9.574 | t = 79 | < 0.001 * |
| Postoperative FS | 1.21 | 8.165 | | |

* There is a highly statistical significant improvement in the Mean scores of FS after operation of metopic synostosis cases.

The result of clinical examination

In an attempt to evaluate the surgical results in this study, we used the classification of Whitaker

et al., 1987 (table 4). Photos 7-8 illustrate the clinical outcome in one case.

Surgical complications are illustrated in table 5. The mortality in this study was 2 patients.

Table (4): Postoperative outcome according to Whitaker et al [8] classification

| Whitaker et al., classification | Metopic (4 patients) | | Unicoronal (6 patients) | | Bicoronal (6 patients) | | total | | Chi Square (χ^2) | P-value |
|---------------------------------|----------------------|------|-------------------------|-------|------------------------|-------|-------|-------|-------------------------|---------|
| | N | % | N | % | N | % | N | % | | |
| Excellent | 3 | 75% | 3 | 50% | 3 | 50% | 9 | 56.3% | 3.00 | 0.808 |
| Good | 1 | 25% | 2 | 33.3% | 1 | 16.7% | 4 | 25% | | |
| Fair | 0 | 0% | 1 | 16.7% | 1 | 16.7% | 2 | 12.5% | | |
| Poor | 0 | 0% | 0 | 0% | 1 | 16.7% | 1 | 6.3% | | |
| Total | 4 | 100% | 6 | 100% | 6 | 100% | 16 | 100% | | |

According to Whitaker et al., classification, most of the operated cases (Metopic, Unicoronal and Bicoronal) showed excellent results (75%, 50% and 50 %) respectively.

Table (5): Operative and post operative complications

| Operative and post operative complication | | Studied Group N (18) |
|---|--------|----------------------|
| Heamatoma | N. (%) | 1 (5.6 %) |
| Dural tear | N. (%) | 5 (27.8%) |
| CSF Leakage | N. (%) | 1 (5.6%) |
| Brain injury | N. (%) | 0 (0%) |
| Infection | N. (%) | 1 (5.6%) |
| Mortality | N. (%) | 2 (11.2%) |

The most common complication was dural tear (27.8 %)

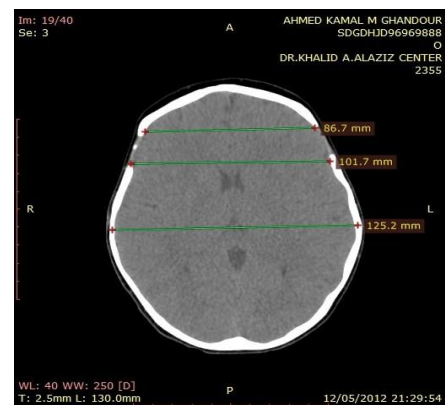
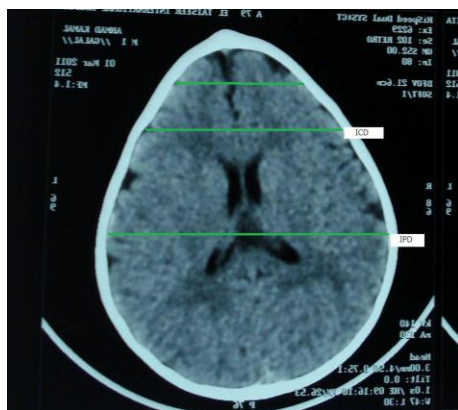
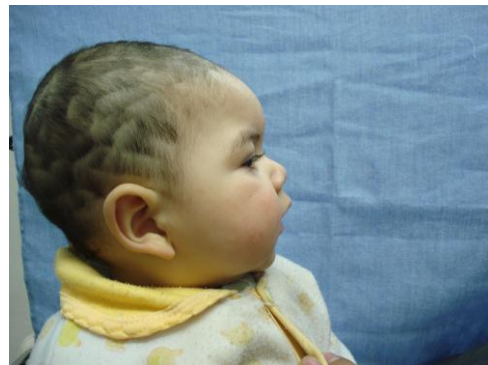
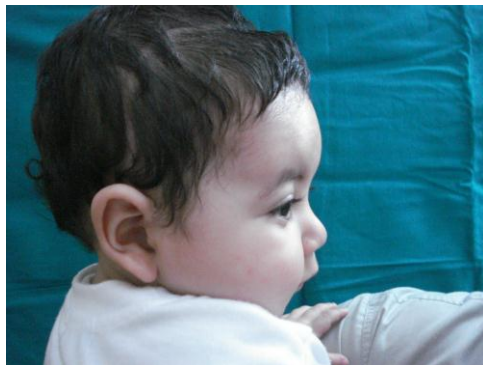
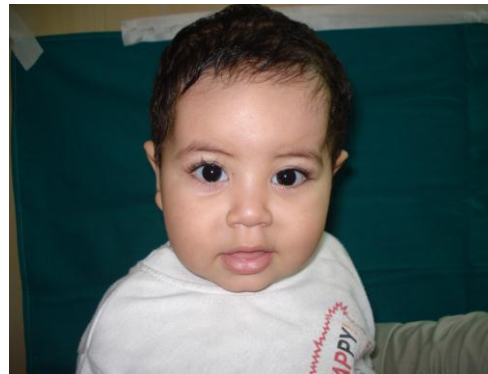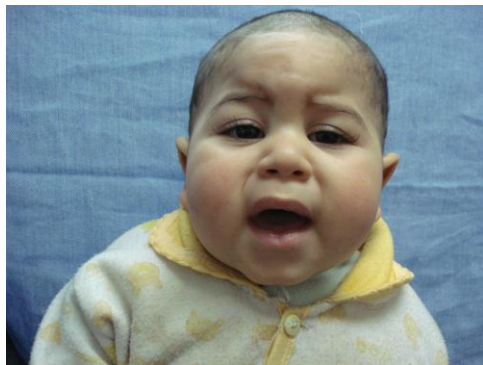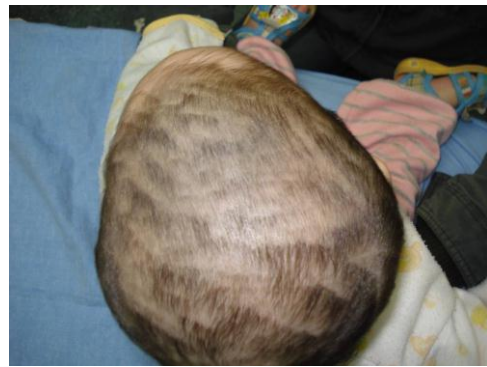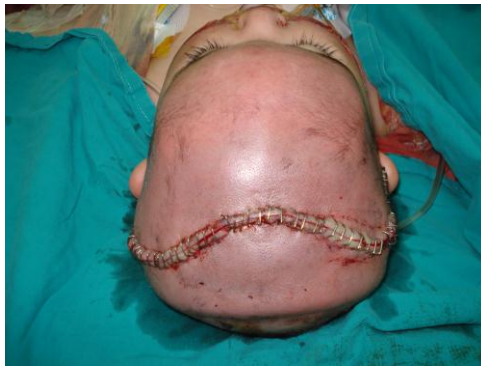Photo 7: CT of patient with metopic craniosynostosis preoperative (left) and post operative (right), showed improvement of the triangular deformity of the frontal bone.



A

B

Photo 8 (A): top view, antroposterior view, and lateral view of male patient aged 10 months with metopic craniosynostosis preoperatively showed the triangular shape of the forehead, the forehead is narrow and keel shaped, and recessed lateral orbital rims, **(B):** top view, Antroposterior view and lateral view of the same patient postoperatively showed the marked improvement of the deformity.

DISCUSSION

Craniosynostosis remains primarily a surgical disease. The goals of therapy are to provide adequate intracranial volume to allow space for brain expansion, to minimize cognitive sequelae and to create an aesthetically normal skull shape [9].

Most craniofacial surgery concentrates on the anterior part of the skull, where there is obvious

clinical deformity. Varieties of the fronto-orbital advancement techniques are performed in most units today [10].

In this study, bilateral fronto-orbital advancement and forehead reshaping was performed in all patients. This technique is accepted worldwide, and it is the favorite of many authors as it facilitates global reshaping through radial sections

in the bone and also permits large reconstructions [1] [11] [12].

Several craniosynostosis series have been reported in literature. Pearsons et al [2] in their study reported a mean age for intervention of 13.6 months. Harrop et al [13] in their study reported a mean age for intervention of 9.2 months. Kadri and Mawla [14] in a study of 116 cases of Syrian children with craniosynostosis, related that surgical intervention was performed in children between 3 and 12 months old. Nonaka et al [15] reported a mean age of 4 years 11 months.

While in study of Schaller et al [16] on craniosynostosis cases the mean age of intervention was 6 months. Also in their series on craniosynostosis, Esparza et al [17] and Ferreira et al [18] the mean age of intervention were 6.75 months and 6.5 months respectively.

In this study of craniosynostosis, the average age of treatment was 10.1 months which is in agreement with Pearsons et al [2] and Harrop et al [13].

In our opinion, that such age at time of surgery; the babies can withstand a lengthy major operation and decreases the anesthetic difficulties. Schaller et al [16] reported in their study the following sex distribution: 72% male and 38% female with male to female ratio of 3: 1. In the same way Goyal et al [19] in 2011 found in their study that ratio of male to female was 1.7: 1. Also Pearsons et al [2] reported in their study the following sex distribution: 54% male and 46% female. Ferreira et al [18] reported in their study sex distribution as follow 70 males and 50 females.

In this study, the sex distribution was 55.6% male and 44.4% females. These findings are in agreement with literature [20], [14], [18], [2], [19], and [16].

Schaller et al [16] in their study reported that sagittal synostosis was 50% of all cases, followed by 27% for metopic, 14% for bilateral coronal and 9% for syndromic craniosynostosis. Also Ferreira et al [18] in their study had the following type of deformity distribution: scaphocephaly 45%, plagiocephaly 22%, trigonocephaly 16%, brachycephaly 13%, and oxycephaly 3%. Kane [21] in (2004), in a craniosynostosis review article, reported the same incidence of the deformity as that was reported by Ferreira et al [18]. Harrop et al (1996) and Kadri and Mawla (2004) found similar results in their series.

While Pearsons et al [2] reported that metopic synostosis represents 22%, 22% for occipital plagiocephaly, 20% for unicoronal synostosis, 15% for bicoronal synostosis, and 11% for sagittal synostosis.

However in the present study, the distributions of deformities were 77.8 % for nonsyndromic craniosynostosis and 22.2% for syndromic craniosynostosis, this was similar to the reported by pearsons et al [2]: 80% for nonsyndromic craniosynostosis and 20% for syndromic craniosynostosis.

Also we found that the unicoronal craniosynostosis represents 38.9% of all cases, 38.9% for bicoronal craniosynostosis, and 22.2% for metopic craniosynostosis.

Although there was variation of frequencies of each type of craniosynostosis in our study to the other studies, a large number study is needed to accurately estimate the frequency of each type of craniosynostosis in our locality.

In this study, the mean operative time was 254 min, this was longer than Schaller et al [16] who reported that the mean duration of operation was 210 min. however Ferreira et al [18] reported longer mean operative time of 286 minutes.

In our series, the average hospital stay after operation was 12.4 days. This was in agreement with the series of Esparza et al. [17] (11.9 days). But this was longer than the hospital stay in the work of Schaller et al [16] and Ferreira et al [18] who had hospital stay of 8.5 days, 6.8 days respectively

In the series of Ferreira et al [18] the morbidity was 9.7% and mortality was 2.6%. Harrop et al [13] reported a morbidity of 0.02% and no mortality in 40 consecutive craniosynostosis operated cases. Kadri and Mawla [14] referred a mortality of 3 patients (2.58%) in a study of 116 children with craniosynostosis.

Esparza et al [17] in a series of 283 patients with craniosynostosis, had a mortality of 0.7 % (2 patients), they reported the most frequent complication was postoperative fever (13.4%), cranial infection (7.5%), subgaleal hematoma (5.3%), dural tears (5%), CSF leakage (2.5%).

In the study of Pearsons et al [2] they found that the percentage of patients with complications and reoperations was 39.2%.

However, Schaller et al [16] in their study have had very low morbidity: small intermittent local reddening of the skin and 1 % with local infection, one patient of 172 patients developed sever postoperative bleeding require re-operation. They had no mortality in their study.

In the present study the most common complications was dural tears account for 27% (5 patients), followed by hematoma at incision line 5.6% (1 patient), subcutaneous infection 5.6% (1 patient), and CSF leakage 5.6% (1 patient). The mortality was 11.2% (2 patients).

Dural tears are a common occurrence after surgical correction of craniosynostosis. Data ranged from 5% to 60%^[17]. To avoid CSF fistulas with their known complications and treatment, dural tears had to be fixed immediately intra-operatively^[17].

The small dural tears in 5 of our 18 cases were sutured immediately by absorbable poly glycolic acid sutures and no CSF fistula was seen in follow-up.

In the last cases of this series, it was observed that surgical time, postoperative complications, hospitalization time, and mortality rates showed a significant reduction. These findings may reflect the development of an organized system among the surgical team members, the anesthesiologist members, and the nursing staff in dealing with this complex and interesting disease.

According to Whitaker et al., 1987 classification the outcome in the present study, at the time of the most recent evaluation, 9 patients (56.3%) achieved excellent aesthetic outcomes (Class I outcome), four patients (25%) achieved good result (Class II outcome), two patients (12.5%) achieved fair results (Class III outcome), and one patient (6.3%) achieved poor result (Class VI outcome). This differ from the surgery outcome in the study of Schaller et al^[16] they achieved the following outcome 97% of the patients have had a good or excellent outcome and 3% achieved limited improvement.

But our post operative outcome results are in agreement with literature, it was similar to the results achieved by McCarthy et al^[23], Boop et al^[24], Renier et al^[25], and Haberl et al^[22].

In the present study we used the CT measurement preoperative and 1-year postoperative to evaluate the surgical outcomes in our operated patients. We used the supra-orbital rim projection measurements either retrusion or protrusion from the longitudinal orbital projection CT view, for both unicoronal and bicoronal synostosis, and the frontal stenosis ratio measurements from the CT film in metopic cynostosis .

We found that the amount of normalization achieved in the supra-orbital rim position 8.8mm and 10.6 mm toward normal position in both bicoronal and unicoronal synostosis respectively. These results are similar to the results of El-Sadek^[6] in his study in planning for preoperative advancement measurements and evaluating his result postoperative in coronal synostosis, he had the following normalization improvement: 8.3 mm and 10.8 mm in both bicoronal and unicoronal synostosis respectively.

Koh et al^[12] reported mean frontal bone advancement of 11 mm in bilateral coronal case.

Lo et al^[26] used quantitative three dimensions CT to assess stability of fronto orbital advancement in bicoronal craniosynostosis. They concluded that rigid fixation at the nasion provide superior stability for bandeau advancement compared with bone graft suture fixation but no assessment to the length of advancement.

On the other hand Sloan et al^[27] in their study, the Outcome was analyzed in terms of residual deformities and irregularities, complications, mortality, as well as the need for additional surgery but no quantitative assessments.

Similarly pearson et al^[2] considered that the complications and reoperation rate were the best manner to evaluate their outcome for primary surgery for craniosynostosis and they did not use any quantitative assessments.

In metopic synostosis patients we measured the frontal stenosis preoperative and postoperative with good improvement as most of our patients after one year had a mean frontal stenosis ratio of 1.21 which is considered the normal ratio as it was advocated by Shimoji and Tomiyama^[7].

Bottero et al^[28] in their study, they used the measurements of frontal stenosis ratio using computed tomography before surgery to assess the severity of the metopic craniosynostosis, they did not use the measures preoperative and postoperative to evaluate the surgical aesthetic outcome.

Again Ruiz-Correa et al^[29] have presented an approach for quantifying the severity of trigonocephaly resulting from metopic craniosynostosis. In their study they compared two indices in quantifying the severity of trigonocephaly between control group and metopic group they did not use their measurement preoperative and postoperative to assess the outcome improvement in the head shape they had achieved.

There were difficulties and limitation in this study must be underlined. Only a small number of patients with craniosynostosis were available for surgery at suitable time. This may be due to low incidence of craniosynostosis and lack of early diagnosis.

Another difficulty was present in this study, the lack of specialized pediatric craniofacial anesthesia staff.

CONCLUSION

A multidisciplinary approach and appropriate training of the clinical surgical staff can minimize the risks and decrease the complications in the treatment of craniosynostosis, leading to a satisfactory outcome. The CT measurements added advantages to evaluate the surgical

outcome. Longer periods of follow up and large number of cases were recommended.

REFERENCES

1. Adamo MA. And Pollack IF. Current Management of Craniosynostosis; *Neurosurg Q* 2009; 19:82–87
2. Pearson, Havlik R J, Eppley B, et al. Craniosynostosis: A Single Institution's Outcome Assessment From Surgical Reconstruction, the journal of craniofacial surgery: 2008; 19: 65 - 71
3. Marsh JL, Kaufman BA. Bilateral coronal craniosynostosis, in Lin K, Ogle RC, Jane JA (eds): *Craniofacial Surgery: A Multidisciplinary Approach to Craniofacial Anomalies*. Philadelphia, Saunders, 2000, pp 218-224
4. Friede H, Lauritzen C, Figueroa AA . Roentgencephalometric follow up after early osteotomies in patients with scaphocephaly. *J Craniofac surg* 1996;7: 96-101
5. Panchal J, Marsh JL, Park TS, et al. Sagittal craniosynostosis outcome assessment for two methods and timings of investigations. *Plast Reconstr Sur* 1999;103 :1574-84
6. El-Sadek AN. Frontoorbital advancement in coronal suture caniosynostosis: a quantitative preoperative assessment. *Annals of pediatric surgery* 2011; 7(4):139-145.
7. Shimoji T, Tomiyama N. Mild trigonocephaly and intracranial pressure: report of 56 patients. *Childs Nerv Syst* 2004; 20: 749-56
8. Whitacker LA, Bartlett SP, Schut L. Craniosynostosis: an analysis of the timing, treatment and complications in 164 consecutive patients. *Plast Reconstr Surg* 1987; 80: 195- 212
9. Speltz ML, Kapp-Simon KA, Cunningham M, Marsh J, Dawson G. Single suture craniosynostosis: a review of neurobehavioral research and theory. *J Pediatr Psychol* 2004; 29(8): 651- 68
10. David DJ. Advances in the management of the craniosynostoses. *ANZ J Surg* 2003; 73:949–957
11. Persing JA. Management considerations in the treatment of craniosynostosis. *Plast Reconstr Surg*. 2008; 121(4):1-11.
12. Koh KS, Kang MH, Yu SC, et al. Treatment of nonsyndromic bilateral coronal synostosis using a multiple bone flap rotation-reposition technique. *J Craniofac Surg* 2004; 15(4):603–608
13. Harrop CW, Avery BW, Marks SM, Putnam GW. Craniosynostosis in babies: complications and management of 40 cases. *Br J Oral Maxillofac Surg* 1996; 34:158- 61
14. Kadri H, Mawla AA. Incidences of craniosynostosis in Syria. *J Craniofac Surg* 2004; 15(4): 703 – 4
15. Nonaka Y, Oi S, Miyawaki T, et al. Indication for and surgical outcomes of the distraction method in various types of craniosynostosis. *Childs Nerv Syst* 2004; 20: 702 -9
16. Schaller BJ, Filis A, Merten HA, et al. Premature craniosynostosis--the role of skull base surgery in its correction. A surgical and radiological experience of 172 operated infants/children. *J Craniofac Surg*. 2012; 40(3): 195-200
17. Esparza J, Hinojosa J, García-Recuero I, et al. Surgical treatment of isolated and syndromic craniosynostosis. Results and complications in 283 consecutive cases. *Neurocirugia (Astur)*. 2008; 19(6): 509-29.
18. Ferreira MP, Collares MV, Ferreira NP, et al. Early surgical treatment of nonsyndromic craniosynostosis. *Surgical Neurology* 2006; 65 (1): 22- 26
19. Goyal K, Chaturvedi A, Prabhakar H. Factors affecting the outcome of patients undergoing corrective surgery for craniosynostosis: a retrospective analysis of 95 cases. *Neurol India*. 2011; 59(6): 823-8.
20. Alderman BW, Lammer EJ, Joshua SC, et al. An epidemiologic study of craniosynostosis: risk indicators for the occurrence of craniosynostosis in Colorado. *Am J Epidemiol* 1988; 128: 431- 8
21. Kane AA. An overview of craniosynostosis. *J Prosth Orthot* 2004; 4: S50–5
22. Haberl H, Hell B, Zöckler MJK, et al. Technical aspects and results of surgery for craniosynostosis. *Zentralbl Neurochir* 2004; 65: 65-74.
23. McCarthy JG, Glasberg SB, Cutting CB, et al. Twenty-year experience with early surgery for craniosynostosis: II. The craniofacial synostosis syndromes and pansynostosis Vresults and unsolved problems. *Plast Reconstr Surg* 1995;96:284
24. Boop FA, Chaddock WM, Shewmake K, el al. Outcome analysis of 85 patients undergoing the pi procedure for correction of sagittal synostosis. *J Neurosurg* 1996;85:50 - 55
25. Renier D, Lajeunie E, Arnaud E, Marchac D. Management of craniosynostosis. *Childs Nerv Syst* 2000;16:645- 58
26. Lo LJ, Marsh JL, Yoon J, et al. Stability of fronto-orbital advancement in nonsyndromic bilateral coronal synostosis: a quantitative three-dimensional computed tomographic study. *Plast Reconstr Surg*. 1996; 98(3):393-405; discussion 406-9.
27. Sloan GM, Wells KC, Raffel C, et al. Surgical treatment of craniosynostosis: outcome analysis of 250 consecutive patients. *Pediatrics*. 1997; 100(1): E2
28. Bottero L, Lajeunie E, Arnaud E et al. Functional outcome after surgery for trigonocephaly. *Plast Reconstr Surg* 1998; 102: 952-8; discussion 59-60
29. Ruiz-Correa S, Starr JR, Lin HJ, et al. New severity indices for quantifying single-suture metopic craniosynostosis. *Neurosurgery*. 2008; 63(2): 318-24

جراحات التعظم المبكر لتدريز الجمجمة بالزقازيق ونتائج ما بعد الجراحة
مصطفى محمد السعدي ، محمد حسن عبد العال، علاء نبيل الصادق، عماد صلاح إبراهيم عبد الفتاح

قسم الجراحة العامة و جراحة التجميل – كلية الطب - جامعة الزقازيق

يعتبر التعظم المبكر لتدريز الجمجمة من أحد أنواع العيوب الخلقية لعظام الجمجمة يحدث نتيجة الالتصاق المبكر للتدريز بين عظام الجمجمة. ويعتبر معدل حدوث المرض بنسبة ١:٢٠٠٠ لكل طفل حي مولود و يحدث نتيجة لعدة أسباب منها العيوب الوراثية والطفرة لبعض الجينات بالإضافة لبعض الأمراض الأخرى. ويوجد منه أنواع متعددة ينتج عنها تغيرات في شكل الجمجمة على حسب الزواير التي تم فيها الالتصاق المبكر ومن هذه الأنواع إما الأحادي (البسيط) أو المتعدد و يوجد منه المنفرد أو ضمن متلازمة لمرض معين. ينتج عن الالتصاق الفحفي تشوهات في شكل الجمجمة والوجه والعين كما ينتج عنه في بعض الحالات ارتفاع في ضغط السائل النخاعي ، تشنجات وأعراض قصور في معدلات الذكاء وغيرها. ومن المتعارف عليه انه لا يوجد علاج دوائي لمثل هذه الحالات و يعتبر العلاج الجراحي الحل الأمثل و يفضل أن يكون قبل سنة من الميلاد وهناك أنواع متعددة للتدخل الجراحي. و تكون أهداف العلاج الجراحي لهذه الحالات هي توفير حجم كاف داخل الجمجمة، لإتاحة الفرصة لنمو الدماغ، وخلق شكل طبيعي للجمجمة مقبول تجميلياً. والهدف من هذه الدراسة هو تقييم نتائج الجراحة لحالات تعظم الدروز المبكر و التحسن في شكل الجمجمة بعد الجراحية في الحالات التي تم علاجها داخل وحدة جراحة التجميل بقسم الجراحة العامة في مستشفيات كلية الطب بجامعة الزقازيق.

تم علاج ما مجموعه ١٨ مريض تعظم الدروز المبكر جراحياً في وحدة جراحة التجميل في مستشفى جامعة الزقازيق حيث تم إجراء تقدم جبهي حجاجي وإعادة تشكيل الجبهة في جميع الحالات. واستند تقييم نتائج ما بعد الجراحة الجراحية على الفحص السريري، وقياسات الأشعة المقطعية قبل وبعد الجراحة باستخدام وضع حافة فوق الحجاج وقياس نسبة تقدمه للامام في حالات التحام العظام الاكليلية، ايضا قياس نسبة التضيق في عظام الجبهة في حالات التحام العظام الجبهي وتصنيف Whitaker et al., 1987

وقد اشتملت هذه الدراسة على ١٨ مريضاً. ١٠ (٥٥,٦٪) منهم من الذكور و ٨ (٤٤,٤٪) من الإناث. كان متوسط العمر في وقت الجراحة ١٠,١١ أشهر. كان متوسط وزن الحالات اثناء الجراحة ٩,٤٧ كجم.

كانت أنواع التشوهات التي وجدت في الدراسة: التحام العظام الاكليلية من جانب واحد في ٧ حالات (٣٨,٩٪)، التحام العظام الاكليلية الثنائية في ٧ حالات (٣٨,٩٪)، والتحام العظام الجبهي في ٤ حالات (٢٢,٢٪). في هذه الدراسة كانت هناك ٤ (٢٢,٢٪) من المرضى في شكل متلازمة آبير.

وفقاً لتصنيف Whitaker et al أظهرت معظم الحالات بعد الجراحة نتائج ممتازة (٥٦,٣٪). وقد لوحظت المضاعفات الجراحية في عدد ٧ مرضى (٣٨,٩٪). في ٥ (٢٧,٨٪) من المرضى كان هناك قطع في الام الجافية، مريض واحد (٥,٦٪) اصيب من تجمع دموي تحت فروة الراس، ومريض واحد (٥,٦٪) اصيب بالتهابات في مكان الجرح. وكان معدل الوفيات في هذه الدراسة ٢,١١٪ (عدد ٢ مرضي). وكان سبب الوفاة هبوط حاد في الدورة الدموية في الحالتين.

التوصيات إن اتباع اسلوب متعدد التخصصات والتدريب المناسب للجراحين و اطباء التخدير يؤدي لتقليل المخاطر والتقليل من المضاعفات في علاج تعظم الدروز المبكر، مما يؤدي إلى نتيجة مرضية.