

## ULTRASOUND GUIDED FOAM SCLEROTHERAPY FOR TREATMENT OF LONG SAPHENOUS VIEN REFLUX

Wael elshimy, Ahmad tawfik , Walid abdalbadie, Medhat allabody, Aymen Samir & Aymen Salem.

Vascular surgery Unit, Faculty of Medicine, Zagazig University.

### ABSTRACT

**Objectives:** To assess the efficacy and safety of ultrasound guided foam sclerotherapy (UGFS) with a long saphenous trunk reflux.

**Methods:** One hundred and seventy cases with primary long saphenous (LSV) trunk reflux underwent foam sclerotherapy. Patients were evaluated using Venous Clinical Severity Score (VCSS) and duplex ultrasound pre procedure, 2 weeks and 6 months following the procedure. Complications were detected and recorded 2 weeks and 6 months following the procedure.

**Results:** Between (September 2010 and December 2011). One hundred and seventy patients with (LSV) trunk reflux underwent foam sclerotherapy 102 females (60%), 68 males (40%). The mean age of patients was 38.8 years, SD (11.35). Two weeks after the first treatment session, the success rate was 93.5%. The failure rate was 6.5%. The complications detected in 23 cases 2 weeks after the first treatment session and included thrombophlebitis in 8 cases, DVT in 3 cases and pain in 12 cases. Six months after the first treatment session, the success rate was 88%. The failure rate was 12%. The complication detected 6 month after the first treatment session was skin staining in 19cases.

**Conclusion:** UGFS is a safe and effective method of treating long saphenous trunk reflux.

**Keywords:** Varicose veins, foam sclerotherapy, duplex ultrasound imaging.

### INTRODUCTION

Varicose veins represents 10-20% of global population.(1) Open surgery is the gold stander in the treatment of the varicose veins.(2)Surgery improves lower limb symptoms, venous haemodynamics and health-related quality of life (HRQL),(3-7) but, it is associated with complications, morbidity, and delayed return to normal activities.(7-17) Thomasset(18) concluded that UGFS represents an alternative offer to surgical treatment for varicose vein and confirmed that it is effective and safe.

The aim of our study to assess the efficacy and safety of UGFS with a saphenous trunk varicose vein in the Vascular Surgery Unit, in Faculty of Medicine, Zagazig University as an initial experience. **ent:**

### PATIENTS AND METHODS

- **In this study,** 170 patients with isolated long saphenous vein (LSV) reflux associated with SFJ incompetence, were selected for ultrasound-guided foam Sclerotherapy (UGFS) at the Vascular Surgery Unit, between September 2010 and December2011.We excluded patients with pregnancy or patients with a history of deep

vein thrombosis, thrombophilia, active thrombophlebitis, allergy to pilodocanol, bronchial asthma, myocardial ischemia, patent foramen oval on echocardiography, arterial insufficiency with an ankle brachial index of less than 0.8 local infection in the area of sclerotherapy, (LSV) diameter not more than 0.8cm and patients with varicosities involving veins other than (LSV). The Institutional Review Board has approved the study and a written informed consent was obtained from the entire patients before the procedure.

#### - **Prior to the procedure:**

All patients were examined clinically to evaluate the severity of the venous disease using VCSS looking for the presence of varicose veins, edema, inflammation, hyperpigmentation and lipodermatosclerosis (19) and examined by duplex to determine the site of reflux along the long saphenous vein.

#### - **2 weeks and 6 months after sclerotherapy:**

Patients were examined clinically for complications of sclerotherapy, evaluation of the severity of the disease using the VCSS, and follow up venous duplex was done

### Duplex evaluation

- All patients included in this study were examined using Color Duplex Ultrasonography from groin to ankle in both lower limbs using 5-10 MHZ linear transducer of Logic 5 machine from General Electric. Venous reflux was considered if venous reflux duration  $\geq 0.5$  Sec. After manual calf compression and release while the patient was standing. Assessment was assigned by Duplex to one of four groups:

- 1- Total occlusion.
- 2- Partial recanalization without reflux.
- 3- Parial recanalization with reflux.
- 4- Total recanalization.

- The procedure was considered to be successful in cases showing total occlusion or partial recanalization without reflux and this criteria of the duplex is similar to other studies.(20)

### UGFS:

- The limb was scrubbed with Povidone-iodine solution. The foam was created using the Tessari technique,(21) mixing 1ml Polidocanol 3% (Ethoxysklerol) with 4 ml of air, using two syringes connected by three way stopcock. Under duplex guidance the great saphenous vein was cannulated by 20 gauge cannula in the distal third of the thigh. Another Butterfly needle is used to cannulate the great saphenous trunk in the leg, if the GSV below

knee show dilatation or reflux. Any large tributaries of the GSV especially, above the level of cannulation of should identified and managed by direct needle injection with foam. Foam was injected as a bolus and its progress along GSV monitored by duplex. A maximum dose of foam injected per session was 10 ml. Passage of foam to the deep venous system is prevented by leg elevation to direct the lighter foam towards the foot by obliteration of SFJ manually and by the duplex probe for 15 min. Immediate changes after successful injection of the vein was detected by duplex showing venospasm and thickening of the wall as a result of the chemical irritation.

- The patients were asked to perform ankle dorsiflexions to clear foam from the deep venous system. The limb was warped by a 15 cm-wide inelastic bandage for 3 days subsequently, 30- 40 mmHg below-knee elastic stockings were used for one month.

- Follow up: Patients were instructed to come for follow up after 2 weeks, and after 6 months. During follow up VCSS is revised to record any changes, and obliteration of the vein is tested by duplex. The occurrence of complications was also recorded.

**Statistical analysis:** Data collected prospectively and stored into an Excel database. Paired t test was used for significance testing to compare among Clinical Severity Score pre-intervention, 2 weeks and 6 months after intervention. Significance was considered when P value < 0.05.

### RESULTS

Between (September 2010 and December 2011). One hundred and seventy patients with great saphenous vein (GSV) reflux underwent foam sclerotherapy 102 females (60%), 68 males (40%). The age of the patients was range from 18 years to 50 years with mean 38.8 years, SD (11.35). The pre intervention VCSS was 7.53, SD (2.42).

**Two weeks:** Two weeks after the first treatment session,

154 presented to the first follow up but, 16 cases were lost (Chart 1). Complete occlusion was detected by duplex to the treated venous segment in 135 cases (135/154) 87.7%. Partial recanalization was detected in 19 cases (19/154) 12.3%. Ten out of 19 cases of partial recanalization showed reflux and complete occlusion was achieved in these cases by a second treatment session that was done in the first follow up. The rest 9 cases showed partial recanalization without reflux and no treatment to them was needed.

The success rate was 93.5%, 2 weeks after the first treatment session, and the failure rate was 6.5% (Table 1).

**Table 1. Success and failure rate of UGFS after 2 weeks**

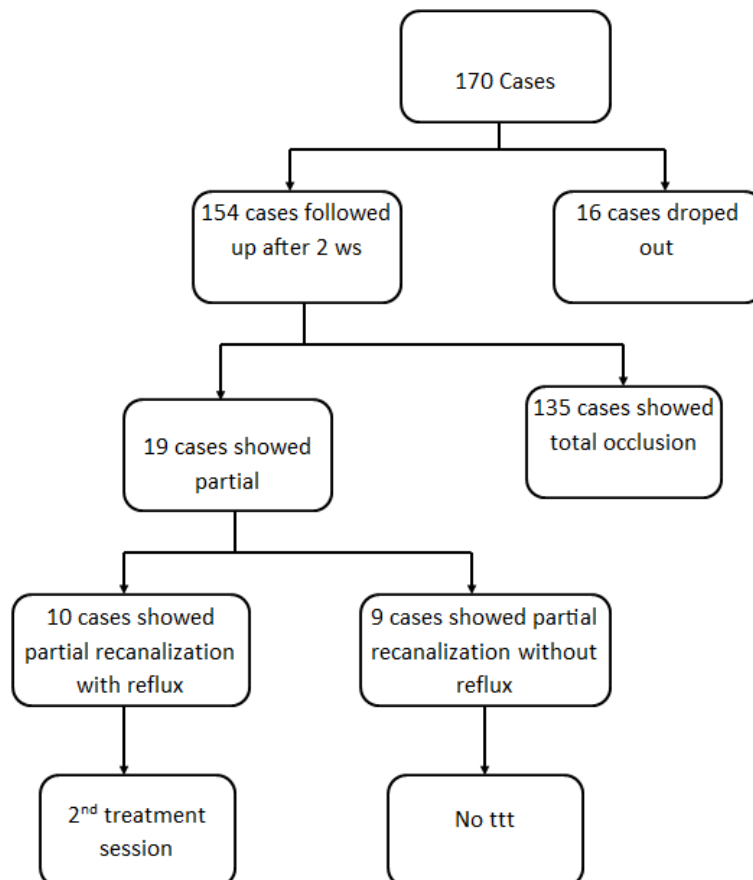
	No	%
Total occlusion	135	87.7%
Partial recanalization without reflux	9	5.8%
Success rate	144	93.5%
Partial recanalization with reflux	10	6.5%
Total recanalization	0	0%
Failure rate	10	6.5%

There was significant improvement of VCSS 2 weeks following the UGFS in comparison to pre-intervention VCSS, where P value was < 0.0001 (Table 2).

**Table 2. The P value compared (2 weeks) VCSS to Pre-intervention VCSS**

	Mean (SD)	P value compared to pre Vs
Pre VCSS	7.53 (2.42)	
VCSS (2 weeks)	2.35 (1.89)	<0.0001

Complications detected in 23 cases (Table 3). Thrombophlebitis detected in 8 cases (8/154) 5.1% and treated by analgesia and compression. DVT detected in 3 cases (3/154) 1.9%, in the calf veins in 2 of them but in the common femoral vein in the third one, all three cases treated with anticoagulant (low molecular weight heparin followed by warfarine for 6 months). Pain detected in 12 cases (12/154) 7.8% and treated by analgesia.



**Chart 1. Results of UGFS at 2weeks.**

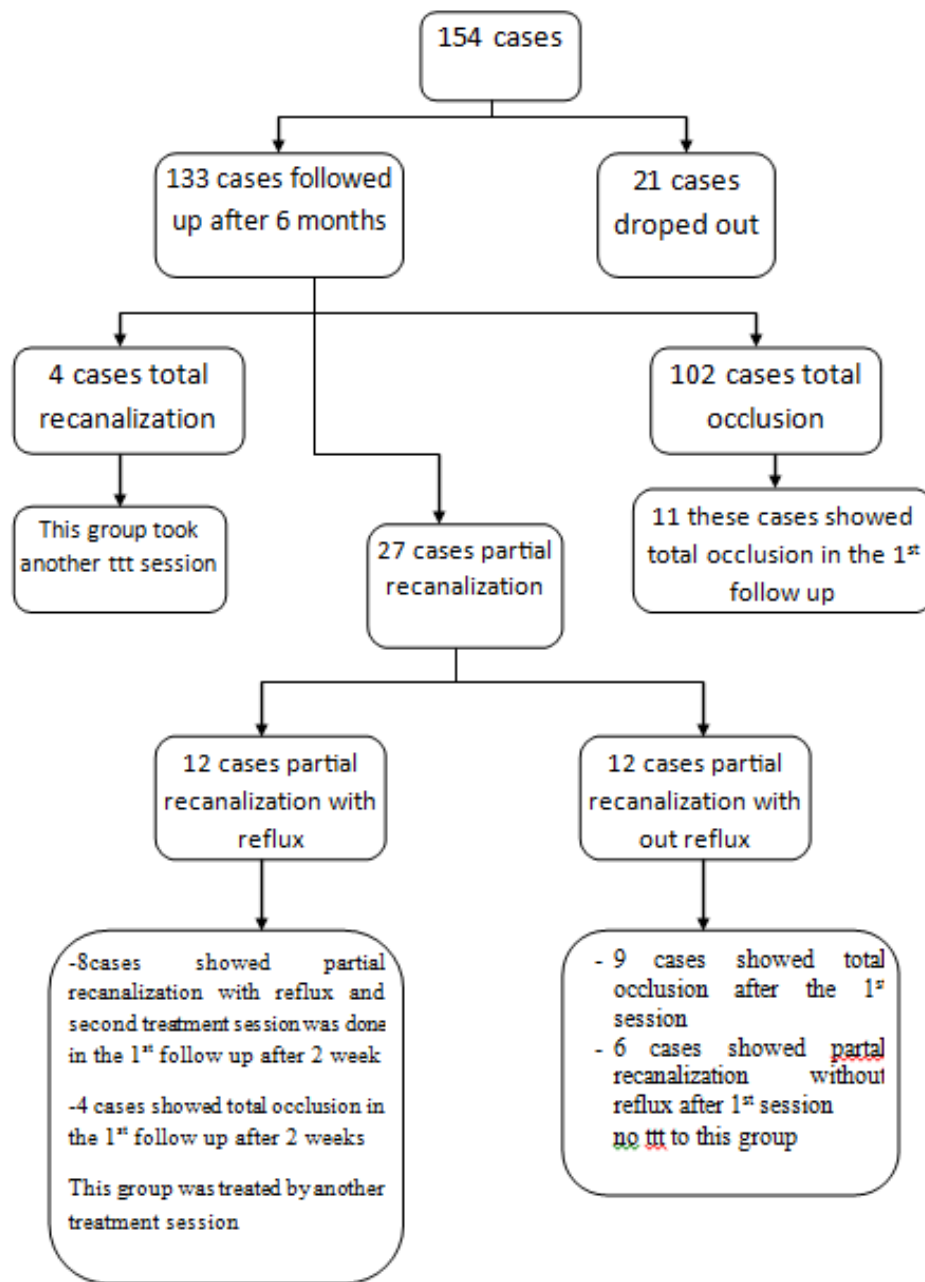


Chart 2. Results of UGFS at six months.

Table 3. Complications of UGFS after 2 weeks.

Complications	No. (%)
Thrombophlebitis	8 (5.1%)
DVT	3 (1.9%)
Pain	12 (7.8%)

**Six months:** Six month after first treatment session 133 cases presented in the second follow up but 21 cases dropped out (Chart 2). The treated veins showed complete occlusion in 102 cases (102/133) 76% after

first treatment session. Total recanalization of the treated veins was in 4 cases (4/133) 3% after the first treatment session and a second treatment session was done. Partial recanalization in the treated veins was

detected in 27 cases, 12 of them with reflux but the rest 15 cases without reflux. Eight of 12 cases whose treated veins showed partial recanalization with reflux after 2 treatment sessions but the rest 4 cases after single first session. All these 12 cases were treated by another treatment session.

Nine out of 15 their treated veins showed partial occlusion without reflux in the

second follow up although; they showed total occlusion in the first follow up. The rest 6 cases their treated veins showed partial occlusion without reflux in the first and second follow up. All those 15 cases took no treatment.

The success rate was 88%, 6 months after the first treatment session, and the failure rate was 12% (Table 4).

**Table 4. Success and failure rate of UGFS after 6 months.**

	No	%
Total occlusion	102	76.6%
Partial recanalization without reflux	15	11.3%
Success rate	117	88 %
Total recanalization	12	9%
Parial recanalization with reflux	4	3%
Failure rate	16	12%

There was significant improvement of VCSS 6 months following the UGFS in comparison to pre-intervention VCSS, where P value was < 0.0001, but there was no significant improvement of the

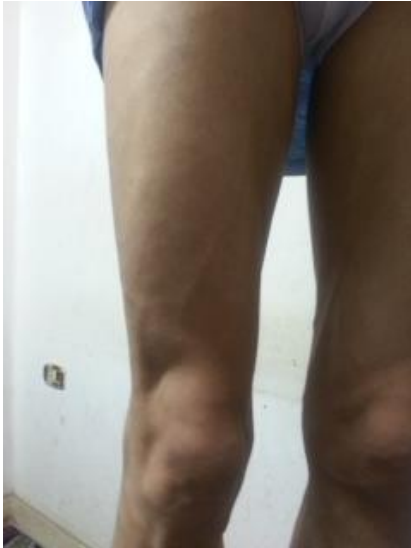VCSS 6 months following UGFS in comparison to 2 weeks VCSS where P value was 0.056 (Table 5). Skin staining was found in 14.3 % of cases (19/133) six month (Table 6).

**Table 5. The P value compared (6 months) VCSS to Pre intervention VCSS and (2 weeks) VCSS.**

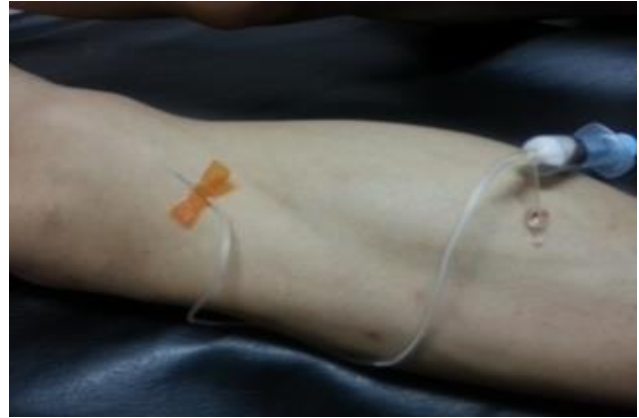	Mean (SD)	P value compared to pre Vs	P value compared to Vs 2 weeks
Pre VCSS	7.53 (2.42)		
VCSS (6 months)	1.90 (2.06)	<0.0001	0.056

**Table 6. Complications of UGFS after 6 months.**

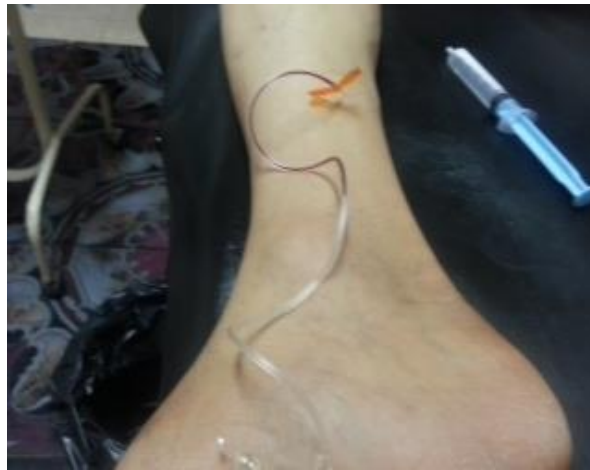Complications	No. (%)
Skin staining	19 (14.3%)



Patient with LSV reflux



Patient with LSV reflux



Cannulation of below knee LSV

### DISCUSSION

UGFS is effective , safe and minimal invasive method for treatment of varicose veins.(21-25) Based on 69 studies in systemic review done by Jia et al,(26) the median rate of target vein occlusion was 87% ( range 60-98) . In another study done by Cabrera et al,(27) 81% of the treated GSV with foam therapy remained occluded after 3 years or more. Also, Thomasset S.C. et al,(18) reported that, with 3 months as a median time of follow up 79% of cases showed complete occlusion of target veins, 14% showed partial occlusion and the rest 6% showed complete patency. The target veins in this

study were the great saphenous vein, small saphenous vein, accessory great saphenous, other unnamed veins or more than a single target vein. Figueiredo, et al,(20) reported that the success rate of cases of sclerotherapy group that showed total occlusion or partial occlusion without reflux was 78% in 6 month following treatment. This study also, reported that the great saphenous vein treated vessels in sclerotherapy group showed a success rate 80%. In the study done by OHare,(28) et al the target vein occlusion was 93% by Doppler at 2 weeks follow up and 74% by Duplex at six month follow up. The treated veins in this study included the great saphenous vein (GSV), small saphenous

vein (SSV), anterior accessory saphenous vein (AASV) or other recurrent veins with significant proximal incompetent deep venous connection. Also, Hamel-Desnos, et al,(29) reported that 100% of cases showed total occlusion and absence of reflux of the target veins at the 28<sup>th</sup> day in both with and without compression groups. The target vein in this study was either GSV or SSV. In our study the success rate after 2 weeks was (93.5%) (144/154), where complete occlusion detected by Duplex in the treated venous segment was found in 135 cases (87.7%) and partial recanalization without reflux in 9 cases (5.8%). The failure rate was (6.5%) (10/154), where the treated veins showed partial recanalization with reflux. Complete occlusion of the treated venous segment of these ten cases was achieved with a second treatment session that was done in the first follow up. Six months after first treatment session, the success rate was (117/133) 88%, where the treated veins showed complete occlusion in 102 cases (102/133) 76.6% and 15 cases (15/133) 11.3% showed partial recanalization without reflux. Failure rate was (16/133) 12% where the treated veins showed complete recanalization in 4 cases (4/133) 3% and partial recanalization with reflux in 12 cases (12/133) 9%.

In our study there was significant improvement of VCSS 2 weeks following the UGFS in comparison to pre intervention VCSS , where P value was < 0.0001. Also, there was significant improvement of VCSS 6 months following the UGFS in comparison to pre intervention VCSS , where P value was < 0.0001, but there was no significant improvement of the VCSS 6 months following UGFS in comparison to 2 weeks VCSS where P value was 0.056 . This result is similar to that reported by Figueiredo et al,(20) who found a statistical significant improvement for pain, oedema and inflammation in both surgery and

sclerotherapy groups, when VCSS was obtained before and after treatment.

Guex, et al(30) reported in large multicentre studies that UGFS associated with a low rate of significant complications. Stroke,(31) anaphylaxis(24) and pulmonary embolism(32,33) were extremely

rare described complications. Morrison, et al,(34) showed that the foam reaches the right ventricle easily with no significant complications. Also, Figueiredo, et al(20) reported that foam was always found in the deep venous system with no complications due to the small amount of foam and to high flow in the deep venous system. In a study was done by Partsch, et al., post-sclerotherapy thrombophlebitis and consequent hyperpigmentation was the most frequent complication associated with foam sclerotherapy.

OHare, et al reported that early complications included 3 injections-site ulcers (2%), that healed and five episodes of temporary visual disturbance (3%), that settled within few minutes. Six months following foam therapy one patient had asymptomatic, thrombosed gastrocnemius vein detected by Duplex after 6 months that treated by warfarin anticoagulant and compression. Eleven legs (11.9%) had residual skin staining and 2 (2%) showed a significant worsening of telangiectases.

In a series of 116 patients Thomasset et al, detected superficial thrombophlebitis in (18%), skin staining in (28%), pain in (14%), DVT in (1%), skin blistering in (1%), an allergic reaction in (1%). This study also, reported that the majority of cases of superficial thrombophlebitis happened when truncal varicosities of >10 mm were treated. The DVT described in this series was below-knee and occurred following treatment of the great saphenous vein and a varix with 15 ml 3% STS. Figueiredo, et al found that respiratory complications represent 2%, local haematoma 5%, scotomas 2%, post- foam extravasation 9%, thrombus with drainage 9% and thrombus without drainage 27%.

Coleridge, reported that, UGFS complications were thrombophlebitis in 5% of patients and treated by analgesia, compression and aspiration of thrombus. DVT occurred in 11 cases, in 10

Of them the thrombus was confined to calf veins and treated by compression with elastic stocking or bandage but in the rest one case, the thrombus was confined to common femoral vein and was treated by anticoagulation. After 6 month follow up, 115 out of 457 legs showed skin pigmentation and 21 legs showed a palpable lump. In our study, in the first follow up 2 weeks after the first treatment session we detect 23 cases with complications. Thrombophlebitis detected in 8 cases (8/154) 5.1% and was treated by analgesia and compression .DVT was detected in 3 cases (3/154) 1.9%, 2 of them in calf veins and one in the common femoral vein, all the three cases were treated with anticoagulant (low molecular weight heparin followed by warfarine for 6 months ). Pain was reported in 12 cases (12/154) 7.8% and was treated by analgesia. In the second follow up assessment 6 months after the first treatment session, complications were detected in 19 cases (19/133) 14.3% with skin staining.

Due to the limitations in our study, as it focused only on LSV, and short term follow up, more researches will be done in the future to study the effect of foam therapy in different sizes veins, to study the long term results of foam therapy and to evaluate the factors affecting the outcome of foam therapy.

In conclusions USGF is and effective procedure in the treatment of long saphenous vein reflux with few complications.

#### REFERENCES

1. Turton EPL, Scott DJA , Richard S, et al. Duplex derived evidence of reflux after varicose vein surgery neoreflux or neovascularisation? Eur J Vasc Endovasc Surg. 1999;17:230-33.
2. Tan V K M, Tan S G. Technique and early results of ultrasound-guided foam sclerotherapy of the long saphenous vein for treatment of varicose veins. Singapore Med J. 2009;50:284-7.
3. Smith JJ, Garratt AM, Guest M, Greenhalgh RM, Davies AH. Evaluating and improving health-related quality of life in patients with varicose veins. J Vasc Surg. 1999;30:710-9.
4. MacKenzie RK, Paisley A, Allan PL, Lee AJ, Ruckley CV, Bradbury AW. The effect of long saphenous vein stripping on quality of life. J Vasc Surg. 2002;35:1197-203.
5. MacKenzie RK, Lee AJ, Paisley A, Burns P, Allan PL, Ruckley CV, et al. Patient, operative, and surgeon factors that influence the effect of superficial venous surgery on disease-specific quality of life. J Vasc Surg. 2002;36:896-902.
6. Sam RC, MacKenzie RK, Paisley AM, Ruckley CV, Bradbury AW. The effect of superficial venous surgery on generic health-related quality of life. Eur J Vasc Endovasc Surg. 2004;28:253-6.
7. Michaels J, Brazier J, Campbell W, MacIntyre J, Palfreyman S, Ratcliffe J. Randomized clinical trial comparing surgery with conservative treatment for uncomplicated varicose veins. Br J Surg. 2006;93:175-81.
8. Sam RC, Silverman SH, Bradbury AW. Nerve injuries and varicose vein surgery. Eur J Vasc Endovasc Surg. 2004;27:113-20.
9. Subramonia S, Lees T. Sensory abnormalities and bruising after long saphenous vein stripping: impact on short-term quality of life. J Vasc Surg. 2005;42:510-4.
10. Wright AP, Berridge DC, Scott DJA. Return to work following varicose vein surgery: influence of type of operation, employment and social status. Eur J Vasc Endovasc Surg. 2006;31:553-7.
11. Wood JJ, Chant H, Laugharne M, Chant T, Mitchell DC. A prospective study of cutaneous nerve injury following long saphenous varicose vein surgery. Eur J Vasc Endovasc Surg. 2005;30:654-8.
12. Beale RJ, Gough MJ. Treatment options for primary varicose veins: a review. Eur J Vasc Endovasc Surg. 2005;30:83-95.
13. Bountouroglou D, Azzam M, Kakkos S, Pathmarajah M, Young P, Geroulakos G. Ultrasound-guided foam sclerotherapy combined with sapheno-femoral ligation compared to surgical treatment of varicose veins: early results of a randomised controlled trial. Eur J Vasc Endovasc Surg. 2006;31:93-100.



14. Corder AP, Schache DJ, Farquharson SM, Tristram S. Wound infection following high saphenous ligation. A trial comparing two skin closure techniques: subcuticular polyglycolic acid and interrupted monofilament nylon mattress sutures. *J R Coll Surg Edinb.* 1991;28:11-5.
15. Biswas A, Clark A, Shields DA. Randomised clinical trial of the duration of compression therapy after varicose vein surgery. *Eur J Vasc Endovasc Surg.* 2007;33:631-7.
16. Tennant WG, Ruckley CV. Causes of legal action following treatment for varicose veins. *Clinical Risk*1997;3:52-4. 16 Ray S. Complaints and litigation following varicose veins surgery. *Clinical Risk.* 2005;11:221-4.
17. Ray S. Complaints and litigation following varicose veins surgery. *Clinical Risk.* 2005;11:221-4.
18. Thomasset SC, Butt Z, Liptrot S, Fairbrother BJ, Makhdoomi KR. Ultrasound Guided Foam Sclerotherapy: Factors Associated with Outcomes and Complications. *Eur J Vasc Endovasc Surg.* 2010;40:389-92.
19. Rutherford RB, Padberg Jr FT, Comerota AJ, Kistner RL, Meissner MH, Moneta GL. Venous severity scoring: an adjunct to venous outcome assessment. *Vasc Surg.* 2000;31:1307-12.
20. Figueiredo M, Araujo S, Barros Jr N, Miranda Jr F. Results of Surgical Treatment Compared with Ultrasound-Guided Foam Sclerotherapy in Patients with Varicose Veins: A Prospective Randomised Study. *Eur J Vasc Endovasc Surg.* 2009;38:758-63.
21. Tessari L, Cavezzi A, Frullini A. Preliminary experience with a new sclerosing foam in the treatment of varicose veins. *Dermatol Surg.* 2001;27:58-60.
22. Hamel-Desnos C, Desnos P, Wollman JC, Ouvry P, Mako S, Allaert FA. Evaluation of the efficacy of polidocanol in the form of foam compared with liquid form in Sclerotherapy of the greater saphenous vein: initial results. *Dermatol Surg.* 2003;29:1170-5.
23. Yamaki T, Nozaki M, Iwasaka S. Comparative study of duplex guided foam Sclerotherapy and duplex-guided liquid Sclerotherapy for the treatment of superficial venous insufficiency. *Dermatol Surg.* 2004;30:718-22.
24. Coleridge-Smith P. Chronic venous disease treated by ultrasound guided foam sclerotherapy. *Eur J Vasc Endovasc Surg.* 2006;32:577-83.
25. Rabe E, Otto J, Schliephake D, Pannier F. Efficacy and safety of great saphenous vein sclerotherapy using standardised polidocanol foam (ESAF): a randomised controlled multicentre clinical trial. *Eur J Vasc Endovasc Surg.* 2008;35:238e45.
26. Jia X, Mowatt G, Burr JM, Cassar K, Cook J, Fraser C. Systematic review of foam sclerotherapy for varicose veins. *Br J Surg.* 2007;94:925-36.
27. Cabrera J, Cabrera J Jr, Garcia-Olmedo MA. Treatment of varicose long saphenous veins with sclerosant in microfoam form: long-term outcomes. *Phlebology.* 2000;15:19-23.
28. O'Hare JL, Parkin D, Vandebroek CP, Earnshaw JJ. Mid Term Results of Ultrasound Guided Foam Sclerotherapy for Complicateand Uncomplicated Varicose Veins. *Eur J Vasc Endovasc Surg.* 2008;36:109-113.
29. Hamel-Desnos CM, BJ Guias BJ, Desnos PR, Mesgard A. Foam Sclerotherapy of the Saphenous Veins: Randomised Controlled Trial with or without Compression. *Eur J Vasc Endovasc Surg.* 2010;39:500-7.
30. Guex J-J, Allaert F-A, Gillet J-L, Chleir F. Immediate and midterm complications of sclerotherapy: report of a prospective multicentre registry of 12,173 sclerotherapy sessions. *Dermatol Surg.* 2005;31:124-8.
31. Forlee MV, Grouden M, Moore DJ, Shanik G. Stroke after varicose vein foam injection sclerotherapy. *J Vasc Surg.* 2006;43:162e4.
32. Bergan J, Pascarella L, Mekenas L. Venous disorders: treatment with sclerosant foam. *J Cardiovasc Surg.* 2006;47:9-18.
33. Cabrera J, Redondo P, Becerra A, Garrido C, Cabrera Jr J, Garcia-Olmedo MA, et al. Ultrasound-guided injection of polidocanol microfoam in the management of venous leg ulcers. *Arch Dermatol.* 2004;140:667-73.
34. Morrison N, Neuhardt DL, Rogers CR, McEown J, Morrison T, Jonhson E, et al. Comparisons of side effects using air and carbon dioxide foam for endovenous chemical ablation. *J Vasc Surg.* 2008;47:830-6.
35. Partsch B. Die Schaumvero'dung: eine renaissance der sklerotherapie. *Phlebologie.* 2004;33:30-6.